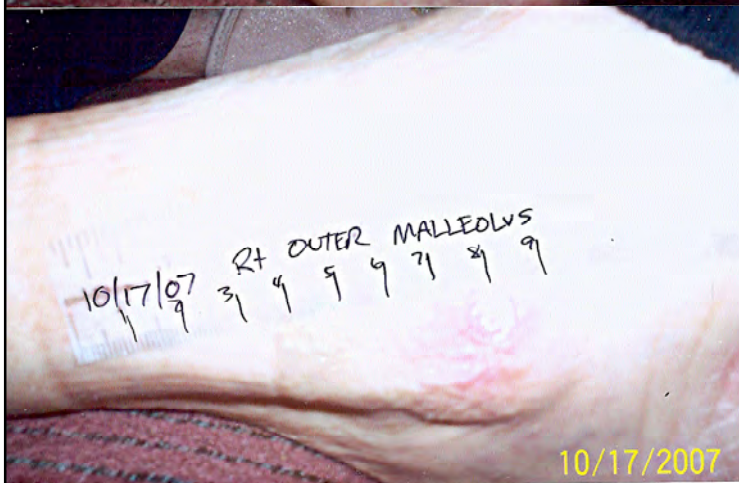
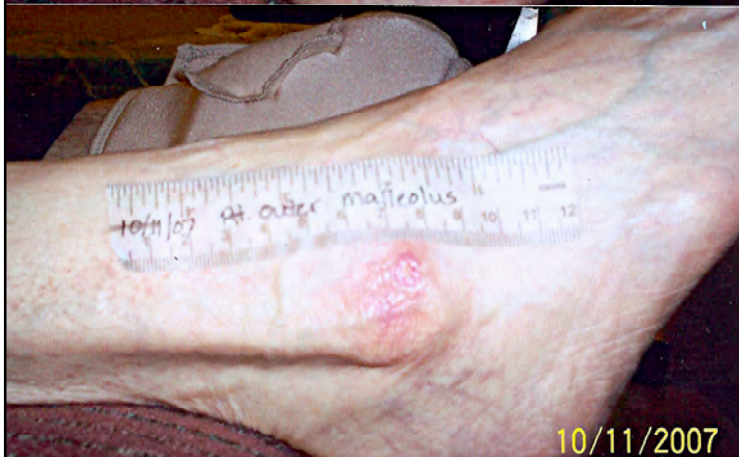
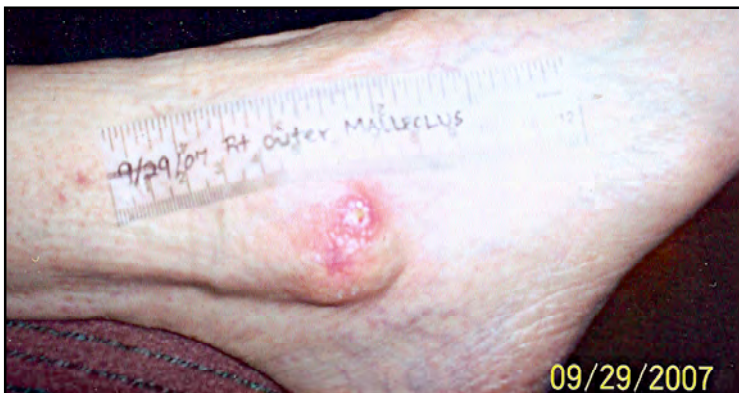
# DermaSaver Case Study

Regency at the Park, College Place, Washington

9-29-07 This resident's feet have external rotation when at rest (in bed or in recliner) and he has had two stage 2 pressure ulcers on the outer malleolus's of both ankles since admission. We have been trying duoderm dressing and booties at HS (cloth covered cotton boots) for approx. 3 months. When the wounds would resolve to a stage 1, the duoderm would be removed, and the booties were continued. But they did not stay in place and constantly had to be re-applied several times throughout the night (interfering with his sleep), and resulting in the return of the the stage 2 ulcers. We would then repeat the process; this has continued for the last 3 months.



We decided to try the DermaSaver Stay-Put Heel Protectors, with this product alone, we had the stage 2's resolved to stage 1's within one week. Plus they remained in place throughout the night. (The resident was very relieved to be able to sleep uninterrupted!) And he was able to ambulate with them on, which allowed him to remain independent with his toileting needs.

10-11-07  
The resident is still presenting with the stage 1 pressure ulcers, but he continues to show signs of resolving without the use of any other dressing. He is still wearing the DermaSaver Stay-Put Heel Protectors 24/7, and is still able to ambulate safely

10-17-07  
After three weeks of using the DermaSaver Stay-Put Heel Protector.s, the wounds on his malleolus's are now resolved. This goal would not have been achieved without this product, as our previous failed attempts with other products have proven. He has some scar tissue over both ankles that will always be a vulnerable area for him, and so the DermaSaver Stay-Put Heel Protectors will continue to be utilized.

We were very pleased with the results of this study, and we plan to use DermaSaver products on a regular basis in our facility.

Thank you for this product!  
Regency At The Park Nursing Staff

